

CASE REPORT

AN UNUSUAL CASE OF DENTIGEROUS CYST: A CASE REPORT

Mahendra Azad¹, MD Minhaj Ahmed Amer², Mohd Umair³

ABSTRACT

Objective: The purpose of this paper is to present an unusual case of dentigerous cyst. **Method:** A dentigerous cyst in relation to unerupted mandibular canines (33 & 43) was enucleated along with removal of canines (33 & 43) under local anesthesia. **Result:** Histopathological evaluation confirmed the diagnosis to be a dentigerous cyst. **Conclusion:** Routine dental check-up which includes the radiological evaluation with the help of an Orthopantomogram is of great asset to the surgeons in identifying any underlying pathology in the maxilla or mandible.

Keywords: Dentigerous cyst, dilacerated unerupted tooth, enucleation, curettage, orthopantomogram.

INTRODUCTION

The dentigerous cyst arises from the dental follicle of an unerupted or developing tooth. It is the second most common odontogenic cyst after the radicular cyst. It is very unusual and rare for any nonmalignant cystic lesion to cross the midline of mandible thus involving both right and left side of the jawbone. Peak incidence is in the age group of 15-30 years. There is a male predilection of 1.6:1.¹

Clinically patients are asymptomatic, and these lesions are normally detected during routine dental checkup in the radiographs. Large cystic lesions may appear as swelling on the affected side of the face. The confirmation of diagnosis is by histopathological examination. The management of dentigerous cyst

depends on the clinical condition and includes total enucleation, marsupialization and decompression. Best treatment option is total enucleation and replacement of the affected bony part of the jaw. The case report illustrates surgical management of a large multilocular dentigerous cyst crossing the midline in the lower jaw in an adult patient.

CASE PRESENTATION

A 34-year old male patient came to the Clove dental clinic with a chief complaint of pain & swelling in lower front jaw for the past 4 weeks. The overall patient's dental and general health was good with non-specific general medical history and no contra-indication to dental treatment & surgical procedure. Intraoral examination revealed presence of retained mandibular deciduous canines and missing permanent canines. Radiological evaluation with the help of an Orthopantomogram revealed presence of radiolucent area in the anterior mandibular region along with the presence of the unerupted mandibular permanent canines extending from 34 to 44 teeth. 31, 32, 34 & 41, 42, 44 teeth roots were involved in the lesion, but teeth were firm with good bone support. Patient was explained about the clinical diagnosis and different treatment options. Surgical profile was done. A written and informed consent was taken from the patient before undergoing the surgical procedure, which in this case was enucleation and curettage with removal of canines followed by placement of bone graft in the residual cystic cavity, & endodontic treatment of lower anterior permanent teeth. One day before the surgery, root canal treatment was carried out for 31, 32, 34, 41, 42, and 44.

SURGICAL PROCEDURE

Under all sterile and aseptic conditions, Articaine with adrenaline 1:1,00,000 was used as local anaesthetic for inferior alveolar nerve block, long buccal, lingual and mental nerve block bilaterally with some local infiltration at the surgical site to achieve anaesthesia & hemostasis. Crevicular incision was made extending from 35 to 45 with bilateral relieving incision distal to 45 and 35. Full thickness mucoperiosteal flap was raised and subperiosteal dissection done. Mental nerve was identified and preserved. Expansion of buccal cortical plate seen, perforation seen at 31 & 41 region, markings were made over buccal cortical plate involving lesion

1. Clinical Director & Chief Consultant, Oral & Maxillofacial Surgeon & Implantologist, Clove Dental, India
2. Consultant Oral & Maxillofacial Surgeon & Implantologist, Clove Dental, Hyderabad
3. Mohd Umair, Consultant Maxillofacial Prosthodontist & Implantologist. Clove Dental, Hyderabad

Corresponding Author

Mahendra Azad

Clinical Director & Chief Consultant, Oral & Maxillofacial Surgeon & Implantologist, Clove Dental, India

Email: mahendra_azad@yahoo.com

for osteotomy and marked buccal cortical plate was osteotomized. In toto cystic lining along with unerupted 33,43 was removed. 33 & 43 were dilacerated. Two daughter cysts were found lateral to the existing lesion below 34 & 44. Apicectomy of 31, 32, 34, 41, 42 & 44 was done. After Enucleation & Curettage, bleeding was seen from right daughter cyst region involving inferior alveolar blood vessels. Pressure pack applied and Inj Trenaxamic acid 500 mg IV was infused. After achieving complete hemostasis. 2 cc Bioss, 2 cc Novabone putty and eight 2 cc PRF was mixed and grafted at the enucleated site and covered with 4 collagen membrane pieces. Primary closure of flap was done with (3-0) silk. Pressure dressing was done with Dynaplast, extraorally at chin region.

Fig. 1: Preoperative OPG, Postoperative OPG

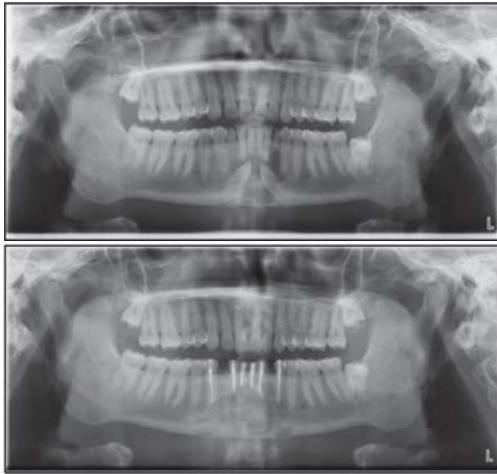


Fig. 2: Intra-Oral, Perioperative Illustration

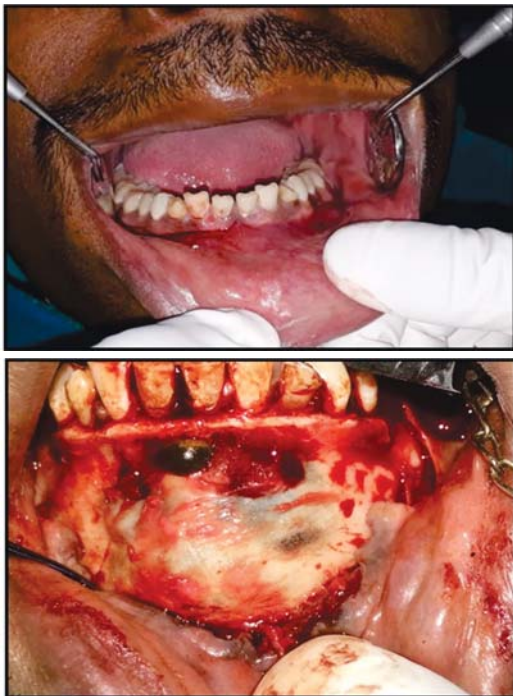

Fig. 3: Perioperative illustration

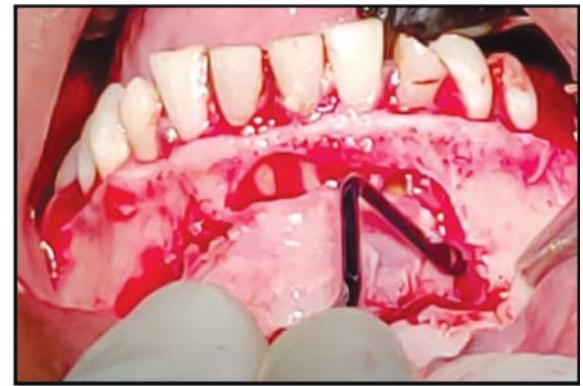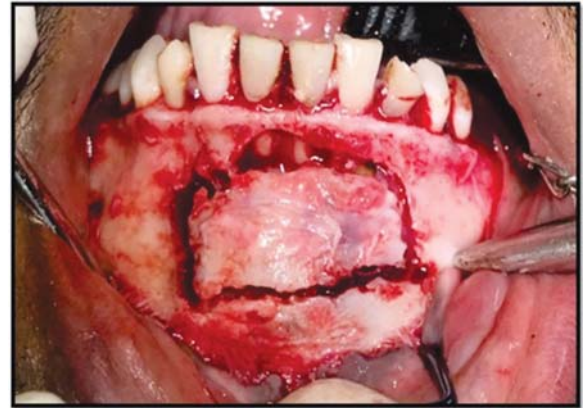


Fig. 4: Perioperative illustration

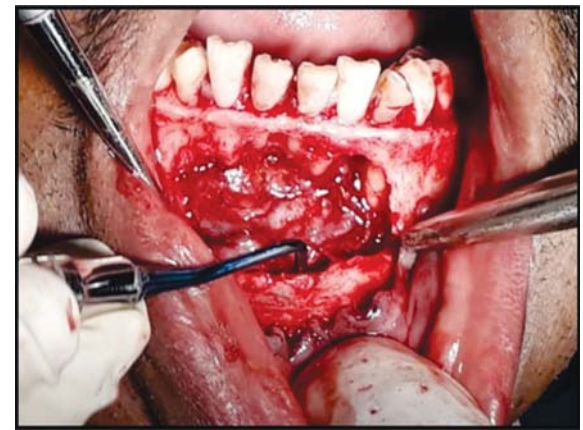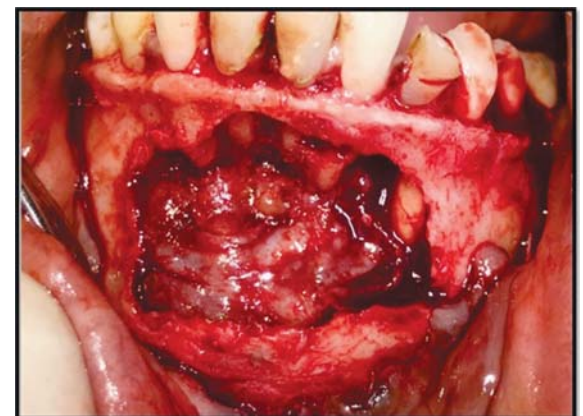


Fig. 5: Perioperative illustration

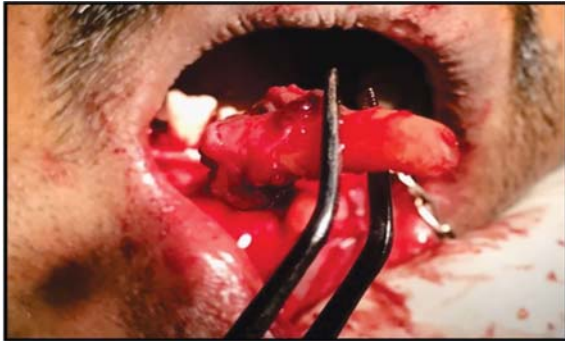
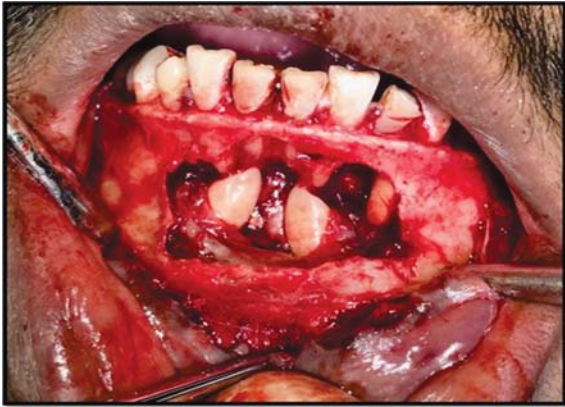
Fig. 6: Surgically extracted unerupted hooked canines & deciduous canines

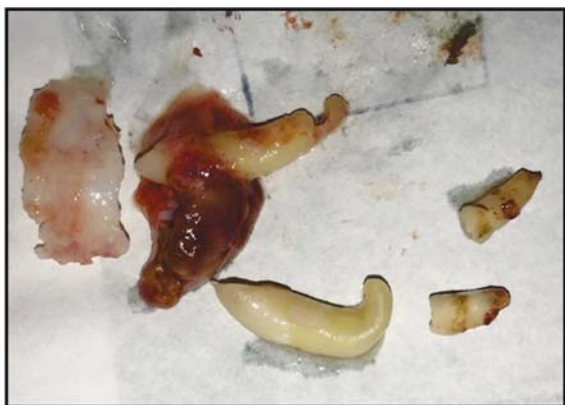
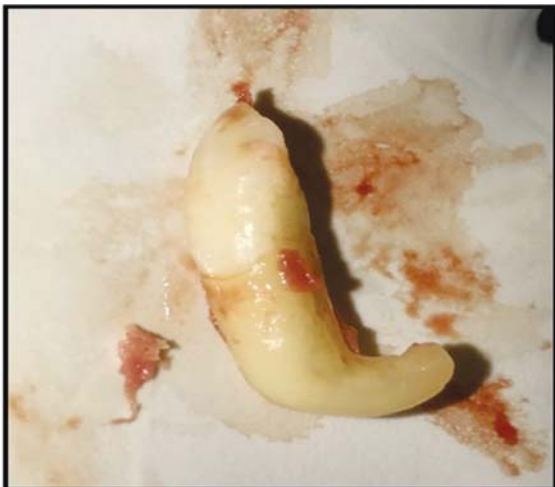
Fig. 7: Perioperative illustration

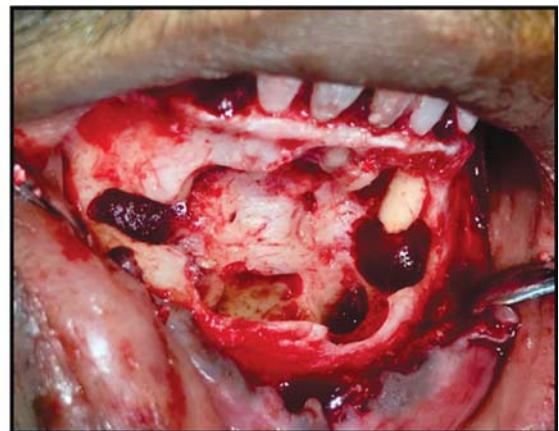
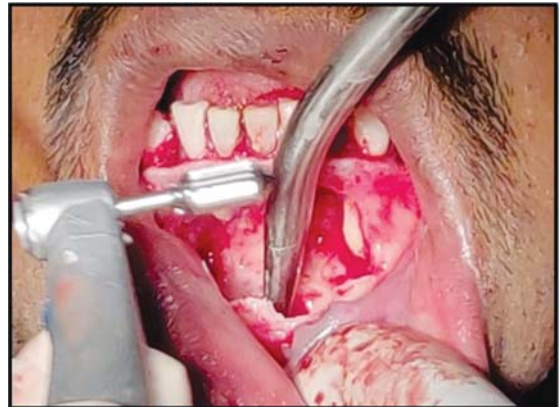
Fig. 8: Perioperative illustration

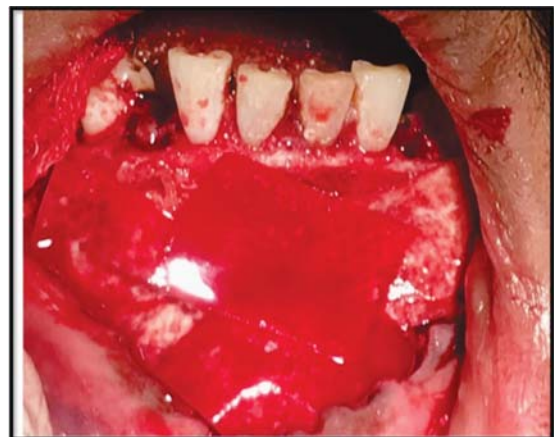
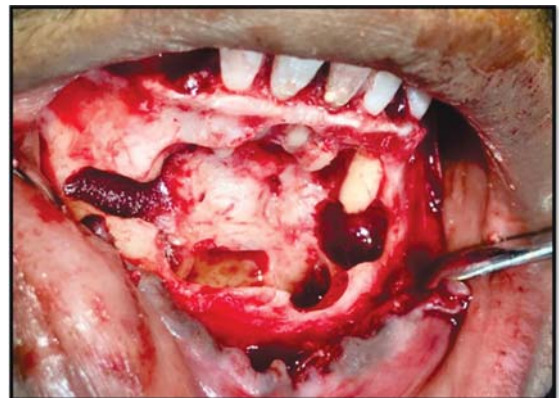
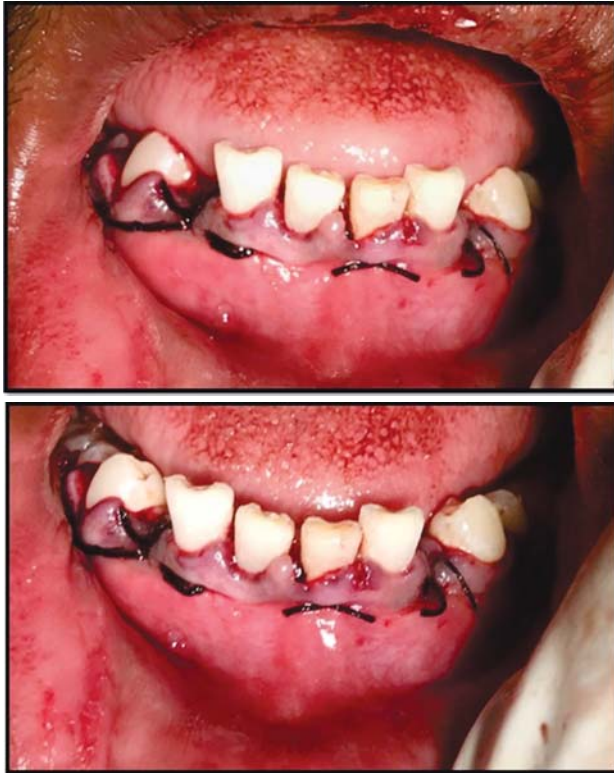

Fig. 9: Perioperative illustration

DISCUSSION

A dentigerous cyst is one that encloses the crown of an unerupted tooth by expansion of its follicle, and is attached to its neck.² A dentigerous cyst may be discovered as an incidental radiographic finding or during oral examination where cortical plate expansion is observed, because this cyst can attain a very large size (10 to 15 cm), some may look as facial deformity. The cysts are not painful unless secondarily infected or their size has led to a pathological fracture. Some expand sufficiently to resorb one or both cortices and are compressible. The tooth from which it arises is clinically absent. Regardless of the degree of resorption of bone or the cyst's size, inferior alveolar nerve sensation in the mandible or superior alveolar nerve plexus in the maxilla is normally not altered unless a pathologic fracture or, more rarely an infection causing paresthesia. Once the cyst is removed, natural bone remodeling will restore normal bone and facial contours.

For the treatment of the dentigerous cyst, the possible alternatives are Enucleation, Marsupialization, or Decompression of the cyst via fenestration. Marsupialization is a rather conservative treatment modality for the treatment of dentigerous cysts, as it decreases the risk of jaw fracture and nerve damage.³ In this case, the unerupted canine roots were hooked & firmly embedded in the lower border of mandible,

marsupialization was not considered as a treatment option. Instead a surgical approach which included enucleation and curettage along with the removal of unerupted mandibular canines was opted.

Large dentigerous cyst may lead to a pathological fracture or may rarely transform into a malignant lesion. Histological examination is considered essential to confirm the clinical and the radiological diagnosis.⁴⁻⁶

CONCLUSION

Some of the challenges which we encountered during the surgical procedure are as follows:

1. Unerupted canines were hooked firmly & embedded in lower border of mandible, little force in removing the unerupted canines or cutting of the bone to relieve the anchorage at root level would have led to immediate fracture of mandible. Since the outer cortical plate was completely resorbed and inner cortical plate was badly eroded by the expansion of the cystic lesion. In this case if the mandible was fractured stabilization of fractured fragments could have been only achieved by a major surgical procedure under General Anaesthesia (GA).
2. 31, 32, 34, 41, 42 & 44 were involved in the cystic lesion, preserving them without any damage to these teeth & healthy bone, removal of the cystic lining in such a scenario is a very difficult task.
3. There were daughter cystic lesions extending in 34, 44 region in the area of mental foramen which were not seen in the radiographic examination. Removing these lesions without damage to the mental nerve was a difficult task, since tunnelling has to be done bilaterally.
4. The medullary bleed & bleed from inferior alveolar blood vessels was quiet challenging.
5. Lesion being approximately 11cm in length and involving the area right up to inferior border of mandible was very big and to replace the lost bone tissue without taking any iliac or rib bone graft.
6. Last but not the least surgery was performed under Local Anaesthesia (LA) in one of our clinics, where there are limitations for carrying out any major surgeries.
7. Bone grafting helps in healing & restoring the shape of the face. All efforts should be made to preserve the teeth which can be saved by endodontic procedure. All patients undergoing routine dental check-up should undergo radiological evaluation to see any underlying pathology.

ACKNOWLEDGEMENT

We sincerely thank the management of Clove Dental, India for their support and all doctors & paramedical staff of Clove Dental Clinic, Governorpet, Vijayawada.

REFERENCES

1. **Marx RE, Stern D.** Oral and maxillofacial pathology: a rationale for diagnosis and treatment. Hanover Park, IL: Quintessence Pub. Co.,; 2012.
2. **Shear M, Speight P.** Cysts of the oral and maxillofacial regions. John Wiley & Sons; 2008 Apr 15.
3. **Pogrel MA.** Treatment of keratocysts: the case for decompression and marsupialization. Journal of oral and maxillofacial surgery. 2005 Nov 1;63(11):1667-73.
4. **Enislidis G, Fock N, Sulzbacher I, Ewers R.** Conservative treatment of large cystic lesions of the mandible: a prospective study of the effect of decompression. British journal of oral and maxillofacial surgery. 2004 Dec 1;42(6):546-50.
5. **Martínez-Pérez D, Varela-Morales M.** Conservative treatment of dentigerous cysts in children: a report of 4 cases. Journal of oral and maxillofacial surgery. 2001 Mar 1;59(3):331-3.
6. **Motamedi MH, Talesh KT.** Management of extensive dentigerous cysts. British dental journal. 2005 Feb;198(4):203-6.